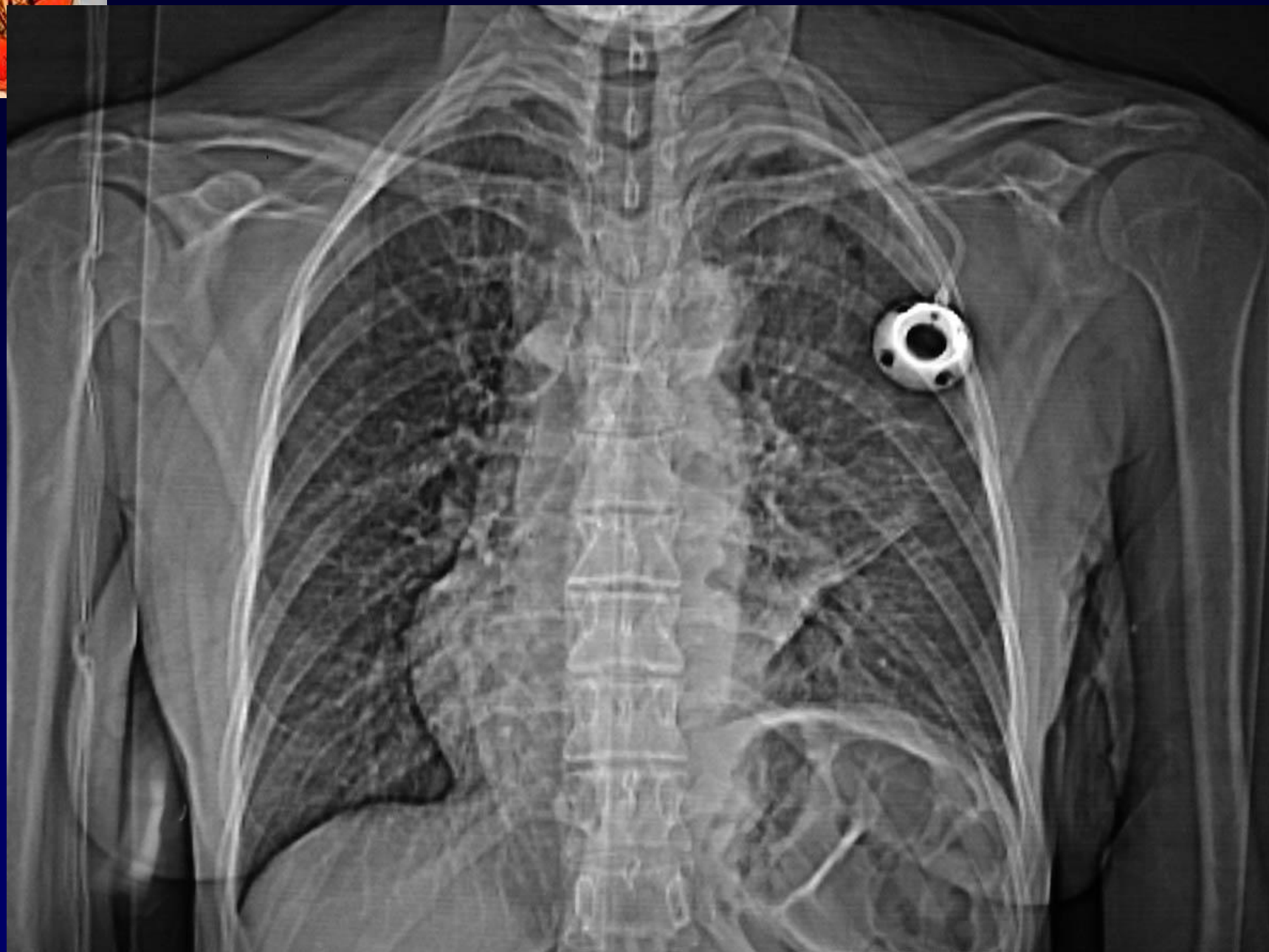

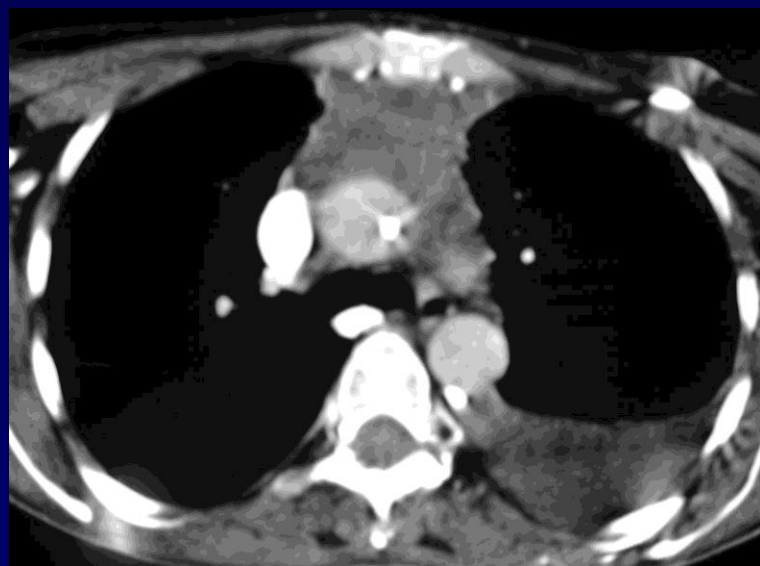
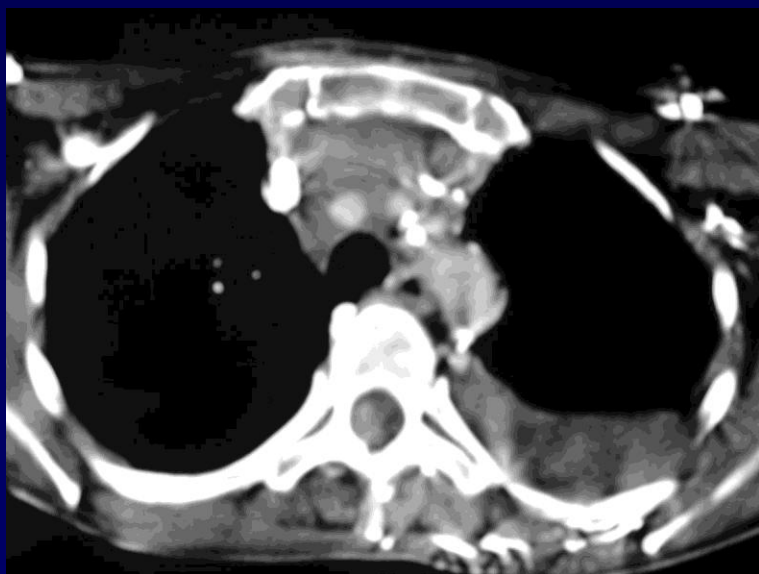
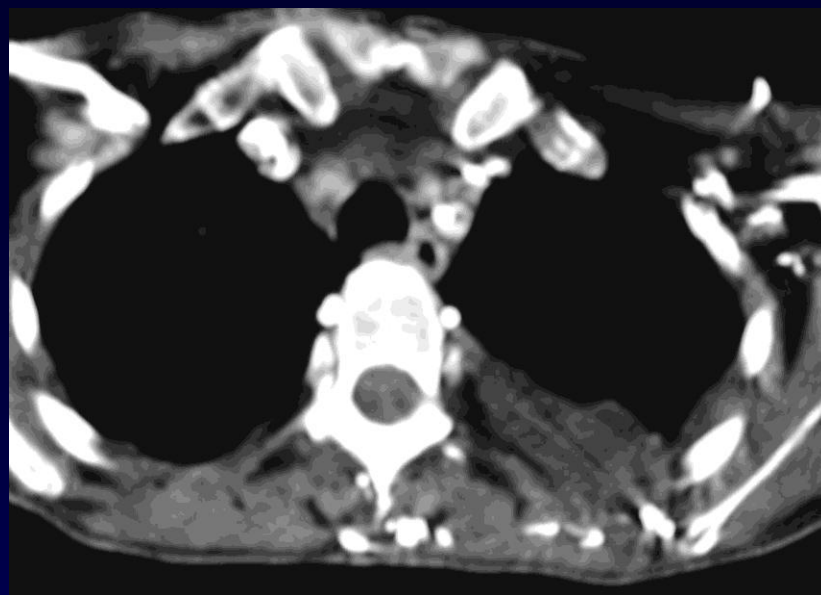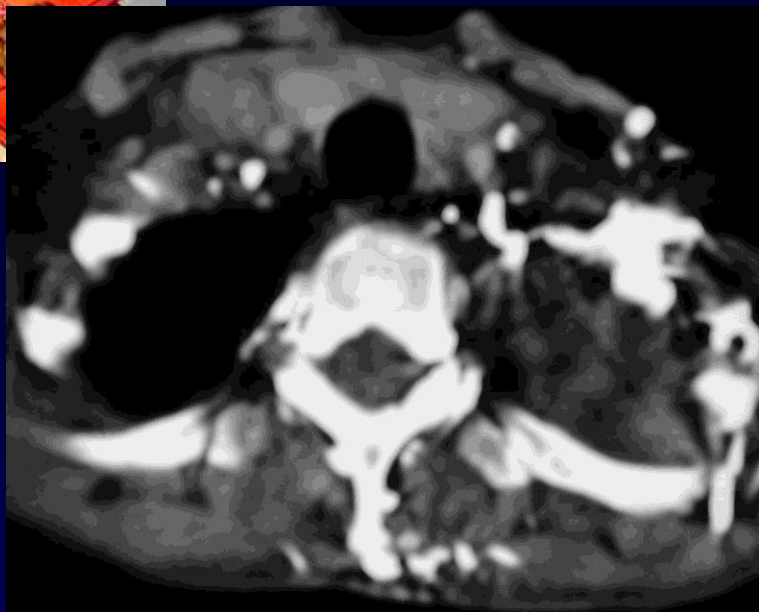


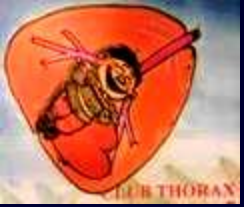J GIRON

Femme, 51 ans

Mise en place d'un port-à-cath pour lymphome médiastinal







Diagnostic ?



**Malposition
artérielle sous
clavière et aortique
du cathéter**

